

Expression of SARS-CoV-2 spike protein in cerebral Arteries: Implications for hemorrhagic stroke Post-mRNA vaccination

Nakao Ota^{a,*}, Masahiko Itani^{b,c}, Tomohiro Aoki^b, Aki Sakurai^d, Takashi Fujisawa^e,
Yasuaki Okada^a, Kosumo Noda^a, Yoshiki Arakawa^c, Sadahisa Tokuda^a, Rokuya Tanikawa^a

^a Stroke Center, Department of Neurosurgery, Sapporo Teishinkai Hospital, Sapporo, Japan

^b Department of Pharmacology, The Jikei University School of Medicine, Tokyo, Japan

^c Department of Neurosurgery, Kyoto University School of Medicine, Kyoto, Japan

^d Disease Control and Prevention Center, National Center for Global Health and Medicine Hospital, Tokyo, Japan

^e Department of Pathology, Sapporo Teishinkai Hospital, Sapporo, Japan

ARTICLE INFO

Keywords:

SARS-CoV-2 spike protein
mRNA vaccines
Hemorrhagic stroke
Spike protein expression
Lipid nanoparticle biodistribution
Long-term vaccine safety
Sex-based differences

ABSTRACT

Background: The rapid deployment of mRNA vaccines for SARS-CoV-2, such as BNT162b2 (BioNTech-Pfizer) and mRNA-1273 (Moderna), provided a critical tool in combating the COVID-19 pandemic. While their short-term safety and efficacy were demonstrated in clinical trials, rare adverse events, including hemorrhagic strokes, have been reported after widespread use. However, the long-term biodistribution and effects of mRNA vaccines remain underexplored.

This study aimed to investigate the long-term presence of SARS-CoV-2 spike protein in brain tissues of patients with hemorrhagic strokes, examining its potential association with mRNA vaccination.

Methods: A total of 19 cases of hemorrhagic stroke from 2023 to 2024 were retrospectively analyzed. Immunohistochemical staining for SARS-CoV-2 spike protein and nucleocapsid protein was performed on tissue samples. In situ hybridization was conducted in selected cases to confirm the origin of spike protein expression (vaccine or viral infection). Vaccination history and SARS-CoV-2 infection status were documented for all cases.

Results: Spike protein expression was detected in 43.8 % of vaccinated patients, predominantly localized to the intima of cerebral arteries, even up to 17 months post-vaccination. While no active inflammatory changes were identified, infiltration of CD4-, CD8- and CD68- positive cells was observed in the spike protein positive vessels. In situ hybridization confirmed the presence of both vaccine-derived mRNA and SARS-CoV-2 virus-derived mRNA, which encode the spike protein, in select cases. Notably, spike protein positivity was observed exclusively in female patients ($P = 0.015$). None of the cases showed nucleocapsid protein positivity, supporting the absence of active viral infection.

Conclusion: Although the possibility of spike protein expression due to asymptomatic SARS-CoV-2 infection cannot be entirely excluded, this study demonstrated prolonged presence of SARS-CoV-2 spike protein in the cerebral arteries following mRNA vaccination. Additionally, some inflammatory cell infiltration was observed in spike-positive vessels. These findings raise significant concerns regarding the biodistribution of lipid nanoparticle-based vaccines and their long-term safety. Global replication studies are urgently required to validate these findings and ensure comprehensive safety evaluations of mRNA vaccines.

1. Introduction

The urgent need for countermeasures against the coronavirus disease 2019 (COVID-19) pandemic has spurred the rapid development of severe acute respiratory syndrome coronavirus 2 (SARS-CoV-2) vaccines of diverse formulations. mRNA vaccines BNT162b2 (BioNTech-Pfizer)

and mRNA-1273 (Moderna/NIAID) have demonstrated high efficacy and safety in clinical trials for COVID-19 prevention [1–3]. Though the emergency approval of the vaccines during the COVID-19 pandemic, humans had no prior experience with mRNA vaccines until the development of the SARS-CoV-2 mRNA vaccine, which marked the first application of this technology. As a result, compared to conventional

* Corresponding author at: Sapporo Teishinkai Hospital, 3-1, Higashi 1, Kita 33, Higashi-ku, Sapporo, Hokkaido 065-0033, Japan..

E-mail address: nakao1980@gmail.com (N. Ota).

<https://doi.org/10.1016/j.jocn.2025.111223>

Received 31 January 2025; Accepted 31 March 2025

Available online 3 April 2025

0967-5868/© 2025 The Author(s). Published by Elsevier Ltd. This is an open access article under the CC BY-NC-ND license (<http://creativecommons.org/licenses/by-nc-nd/4.0/>).

vaccines such as inactivated or live-attenuated vaccines, there is limited experience and their long-term safety remains unknown.

The risk of stroke associated with SARS-CoV-2 infection has been reported since the early stages of the pandemic [4–7]. In particular, the risk of ischemic stroke due to hypercoagulation state and endothelial injury has been highlighted [7,8]. However, although thrombotic or hemorrhagic strokes following SARS-CoV-2 mRNA vaccination were not observed during the phase 2–3 clinical trial [3], several cases of such strokes have been reported after widespread clinical use. These reports are primarily limited to early complications occurring within approximately one month after vaccination [9–12].

We encountered a case in which the SARS-CoV-2 spike protein was detected via immunohistochemical staining in brain tissue samples obtained during surgery from a patient presenting with an atypical form of cerebral hemorrhage several months after vaccination, despite no history of SARS-CoV-2 infection (Fig. 1). This observation prompted us to retrospectively and prospectively collect tissue samples from patients with hemorrhagic stroke to investigate spike protein expression and its potential association with vaccination, SARS-CoV-2 infection, and the pathogenesis of hemorrhagic stroke.

2. Materials and methods

2.1. Study design and population

From March 2023 to April 2024, we retrospectively and prospectively included all cases of patients with hemorrhagic stroke or autopsy cases who underwent surgery at Sapporo Teishinkai Hospital, with approval from the Institutional Review Board of Sapporo Teishinkai Hospital (#2023–26) and the Institutional Review Board of the Jikei University (#35–345[11977]). Written informed consent was obtained from all patients or their legal representative. During surgery, brain tissues or other samples were collected from damaged areas while removing the hematoma or repairing aneurysm. Information regarding

the vaccine type and vaccination dates was retrieved from municipal vaccination records, including the dates and lot numbers (Supplemental Table 1).

One case (Case 18) involved an autopsy following death from subarachnoid hemorrhage. Vaccination records were unavailable for this case; therefore, the “time from last vaccination to surgery” was marked as NA. According to information obtained from the family during the interview, the patient had been vaccinated 15 months prior to surgery.

SARS-CoV-2 infection history was confirmed only for cases where patients had been diagnosed as positive via polymerase chain reaction (PCR) test or antigen testing at a medical institution. Therefore, cases with mild cold-like symptoms or undiagnosed infections due to the absence of medical consultation were considered as having no history of SARS-CoV-2 infection.

2.2. Histology and immunohistochemical staining

Biopsy from brain tissue, cerebral artery or other samples and autopsy tissue samples were fixed in formalin and embedded in paraffin (FFPE), and sectioned. Once unstained slides were generated and initial Hematoxylin and Eosin (H&E) stained sections were analyzed. Immunohistochemistry was performed After de-paraffinization and blocking with 10 % donkey serum (#AB_2337258, Jackson ImmunoResearch, West Grove, PA), slices were incubated with primary antibodies followed by incubation with secondary antibodies conjugated with fluorescence dye. Finally, fluorescent images were acquired on a confocal fluorescence microscope system (LSM880 or LSM980, Carl Zeiss, Oberkochen, Germany).

Primary antibodies used were as follows; rabbit monoclonal anti-Nucleocapsid antibody (Clone; HL344, #MA5-36251, Thermo Fisher Scientific, Waltham, MA), and mouse monoclonal anti-Spike Protein antibody (Clone; GT263, #MA5-36245, Thermo Fisher Scientific).

Secondary antibodies used were as follows; Alexa Fluor 488-conjugated donkey anti-mouse IgG H&L antibody (#A21202, Thermo Fisher

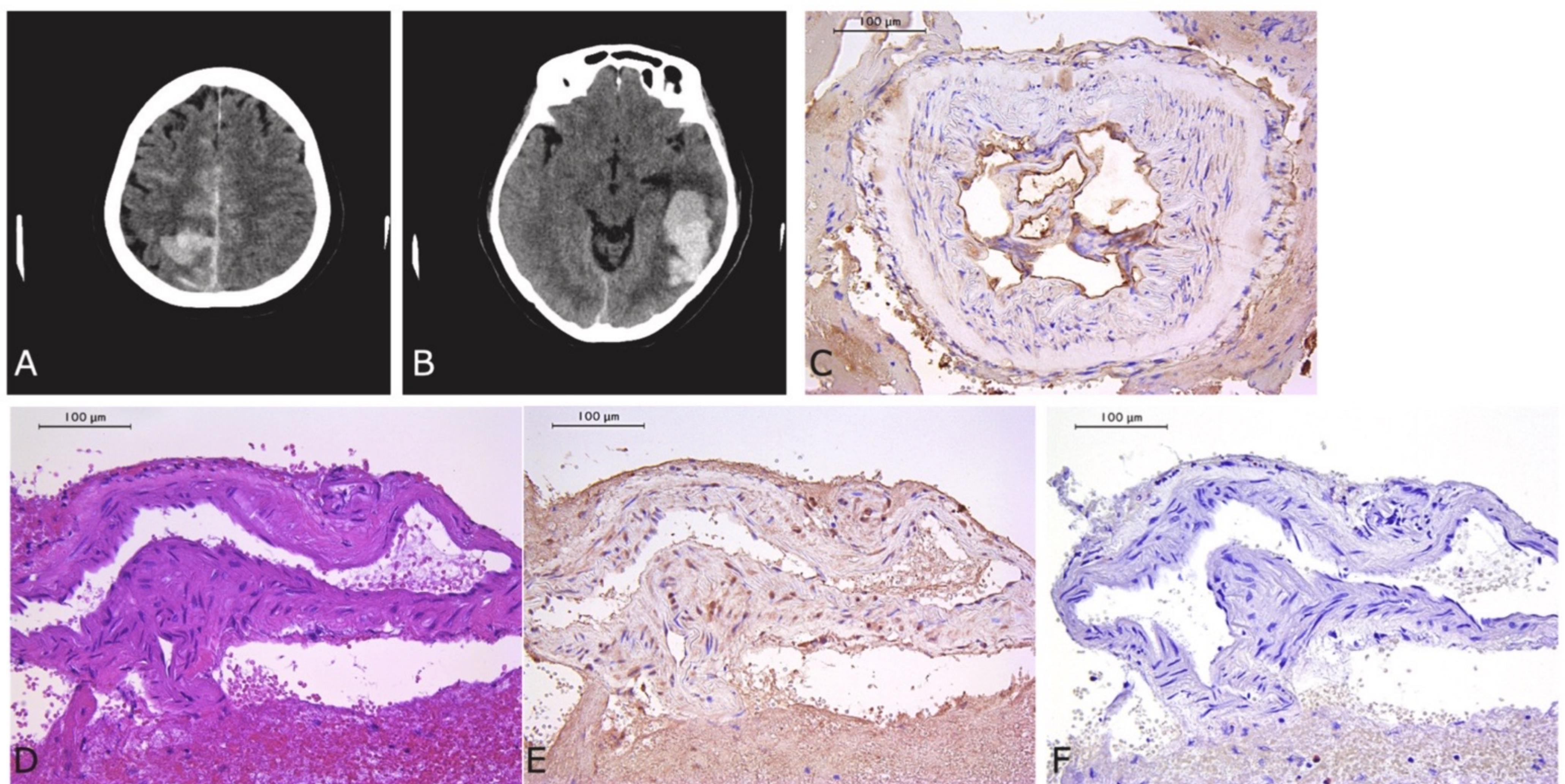


Fig. 1. Atypical intracerebral hemorrhage case expressing the COVID-19 spike protein. A, B: Computed tomography reveals intracerebral hemorrhage along with subarachnoid and subdural hemorrhages in the left temporal lobe and right parietal lobe. C: Immunohistochemical staining using MA5-35946 (mouse monoclonal [1A9] S2 domain) shows positive staining for the spike protein in the intima of the vessel. D: Hematoxylin and eosin staining of brain tissue. E: Immunohistochemical staining using MA5-35946 (mouse monoclonal [1A9] S2 domain) demonstrates positive staining for the spike protein in the intima of the vessel and smooth muscle. F: Direct Fast Scarlet staining shows negative results for amyloid protein.

Scientific), Alexa Fluor 647-conjugated donkey anti-rabbit IgG H&L antibody (#A31573, Thermo Fisher Scientific).

2.3. In situ hybridization

Since some cases showed positive staining for the SARS-CoV-2 spike protein via immunohistochemical staining, we planned to perform in situ hybridization to differentiate whether the spike protein expression was due to SARS-CoV-2 infection or mRNA vaccination. To address this, in situ hybridization was conducted on three cases (Case 4, 5 and 15) where the infection history was unclear, a significant amount of time had elapsed since vaccination, yet spike protein was still detected through immunostaining.

For in situ hybridization, slices from human specimens were prepared as in above. After de-paraffinization, in situ hybridization was done using a RNAscope™; Duplex Reagent Kit (#322430, Advanced Cell Diagnostics, Inc., Newark, CA) and probes to detect mRNA from vaccine (#1215391, Advanced Cell Diagnostics) and to detect mRNA encoding spike protein in SARS-CoV-2 (#848561, Advanced Cell Diagnostics) from the company. The probe to detect the gene encoding Peptidylprolyl Isomerase B (#313901, Advanced Cell Diagnostics) was used as a positive control experiment and one to detect bacterial gene for Dihydrodipicolinate Reductase (dapB) from Bacillus subtilis strain SMY (#310043, Advanced Cell Diagnostics) as a negative control experiment. The images were acquired by a microscopic system.

The negative control for in situ hybridization was obtained from Case 15.

2.4. Statistical Analysis

Data are presented as the mean ± standard deviation, median (interquartile range), or number of patients (%), as appropriate. Fisher’s exact test was employed to analyze the association between spike protein positivity and sex differences. Statistical analyses were performed using IBM SPSS Statistics for Mac, version 27.0 (IBM Corp., Armonk, NY, USA). A P-value of < 0.05 was considered statistically significant.

3. Results

Nineteen cases were included in the study, with details summarized in Table 1. Of these, 10 were intracerebral hemorrhage, subarachnoid hemorrhage in 6 cases, hemorrhage due to arterio-venous malformation in 2 and one case hemorrhage due to cavernous malformation. The mean age was 58.9 (±18.9) years, with a predominance of females (14 cases, 73.7 %). Sixteen patients had received an mRNA vaccine, while three had not. Among the 16 vaccinated patients, the median number of vaccinations was 4.0 (IQR 2.0), and the mean time from the last vaccination to surgery was 10.8(±6.8) months.

3.1. Immunohistochemical staining for spike protein and nucleocapsid protein

Fig. 1 shows an illustrative case in which SARS-CoV-2 spike protein was detected via immunohistochemical staining in brain tissue samples (Case 9). A 72-year-old woman with a history of seven SARS-CoV-2

Table 1
Study Cases: Baseline Characteristics, Immunohistochemical Staining Results, and Histories of Vaccination and COVID-19 Infection.

Case	Age	SEX	Diagnosis	Sample	History of previous diagnosis of COVID19 infection	History of mRNA Vaccinations	Number of Vaccinations	Time from last vaccination to surgery (month)	Immunostaining Spike protein/ Nucleocapsid
1	25	Female	Subcortical hemorrhage	AVM	NO	YES	3	5	Negative/ Negative
2	75	Male	Putaminal hemorrhage	Brain tissue	NO	YES	4	7	Negative/ Negative
3	50	Female	Putaminal hemorrhage	Brain tissue	NO	YES	2	22	Negative/ Negative
4*	70	Female	Subarachnoid hemorrhage	Cerebral artery	NO	YES	3	17	Positive/ Negative
5*	79	Female	Cerebellar hemorrhage	Brain tissue	NO	YES	5	12	Positive/ Negative
6	49	Female	Putaminal hemorrhage	Brain tissue	NO	NO	0	–	Positive/ Negative
7	53	Male	Cerebellar hemorrhage	Brain tissue	NO	YES	3	18	Negative/ Negative
8	63	Male	Putaminal hemorrhage	Brain tissue	NO	NO	0	–	Negative/ Negative
9	72	Female	Subcortical hemorrhage	Brain tissue	NO	YES	7	5	NA
10	23	Female	Intraventricular hemorrhage	AVM	YES	NO	0	–	Positive/ Negative
11	67	Male	Putaminal hemorrhage	Brain tissue	NO	YES	4	2	Negative/ Negative
12	81	Female	Subarachnoid hemorrhage	Brain tissue	NO	YES	7	2	Positive/ Negative
13	50	Female	Subarachnoid hemorrhage	Cervical lymph node	NO	YES	5	3	Negative/ Negative
14	55	Female	Subarachnoid hemorrhage	Brain tissue	NO	YES	3	21	Negative/ Negative
15*	71	Female	Putaminal hemorrhage	Brain tissue	NO	YES	4	11	Positive/ Negative
16	88	Female	Subcortical hemorrhage	Brain tissue	NO	YES	7	8	Positive/ Negative
17	47	Male	Brain stem hemorrhage	Cavernous malformation	YES	YES	4	15	Negative/ Negative
18	72	Female	Subarachnoid hemorrhage	Brain tissue	NO	YES	3	NA	Positive/ Negative
19	30	Female	Subarachnoid hemorrhage	Brain tissue	NO	YES	5	14	Positive/ Negative

AVM; arterio-venous malformation, *; patients with being performed in situ hybridization

vaccinations and no history of COVID-19 infection underwent emergent clot removal surgery for an intracerebral hemorrhage in the left temporal lobe. Specimens were collected from the area surrounding the hemorrhage. Based on the immunohistochemical staining results, cerebral amyloid angiopathy was ruled out, and positive staining for the spike protein was observed in the intima of the vessel and smooth muscle.

Fig. 2 shows the results of immunostaining for SARS-CoV-2 spike protein and nucleocapsid protein. Among the 16 patients with a history of mRNA vaccination, 7 cases (43.8 %) showed a positive staining for the SARS-CoV-2 spike protein (Cases 4, 5, 6, 10, 12, 15, 16, 18, and 19), with no positive staining for the nucleocapsid protein. Among the 3 patients without a history of mRNA vaccination (Case 6, 8 and 10), 2 cases (66.7 %) were positive staining for the SARS-CoV-2 spike protein (Case 6 and 10) and negative staining for nucleocapsid protein. The remaining patient negative staining for the nucleocapsid protein but had a history of a SARS-CoV-2 infection (Case 8).

In the positive staining of the spike protein cases, all spike protein was expressed in the intima of the cerebral arteries. No obvious aggressive inflammatory cells infiltration suggesting active vasculitis was observed. However, in the spike protein-positive cases, whether with or without history of vaccination, findings such as CD4-positive T-cell and CD68-positive cells infiltration into the intima, as well as CD 8-positive cells infiltration into the adventitia, were noted. In the spike protein negative cases, no such findings were observed (Figs. 3 and 4).

Among the 18 cases, excluding the case of defective specimen, all cases with positive spike protein staining (9 females and 0 males) were female (Fisher’s exact test; P = 0.015) (Table 1).

3.2. In situ hybridization

In situ hybridization was conducted using control probes, SARS-CoV-2 vaccine mRNA-specific probes, and spike protein mRNA probes for Cases 4, 5, and 15. These cases showed positive staining for the SARS-CoV-2 spike protein and negative for the nucleocapsid protein in immunohistochemical staining. It had been 17, 12, and 11 months since

their last mRNA-1273 or BNT162b2 vaccination. In all three cases, in situ hybridization revealed the presence of both mRNA from the vaccine and SARS-CoV-2 viral RNA in the intima (Fig. 5).

4. Discussion

The present study revealed that spike protein derived from the mRNA vaccine was expressed in the intima of the cerebral arteries in patients with hemorrhagic stroke, even 17 months after vaccination. The relationship between hemorrhagic stroke and the expression of spike protein remains unclear, as the excised samples were not from hemorrhagic lesions themselves, and there was no obvious evidence of active vasculitis, but showed infiltration of some inflammatory cells in the spike protein-positive vessels. To the best of our knowledge, this is the first report of its kind worldwide.

There are reports of hemorrhagic stroke complications occurring in the acute stage, within one month after vaccination. These reports are primarily based on circumstantial evidence of atypical strokes shortly following vaccination [9,10,12]. A large epidemiologic study in Hong Kong also demonstrated that the BNT162b2 (Pfizer-BioNTech) vaccine was associated with an increased risk of hemorrhagic stroke during the 14–27 days after the first dose and the 0–13 days after the second dose. However, the study also concluded that the incidence of thromboembolic events and hemorrhagic stroke was lower among vaccine recipients compared to individuals who tested positive for SARS-CoV-2, affirming the vaccine’s safety [10]. To date, there have been no reports of long-term complications following SARS-CoV-2 vaccination.

The reported mechanism of the ischemic and hemorrhagic stroke due to spike protein of SARS-CoV-2 are that, the SARS-CoV-2 spike protein has been implicated in disrupting blood–brain barrier integrity through RhoA activation, potentially contributing to neurological complications in COVID-19 patients [4]. The virus’s binding to angiotensin converting enzyme-2 (ACE2) receptors can lead to abnormal blood pressure regulation, increasing the risk of hemorrhagic stroke [7]. COVID-19-associated coagulopathy, characterized by elevated D-dimer and inflammatory markers, may predispose patients to both ischemic and

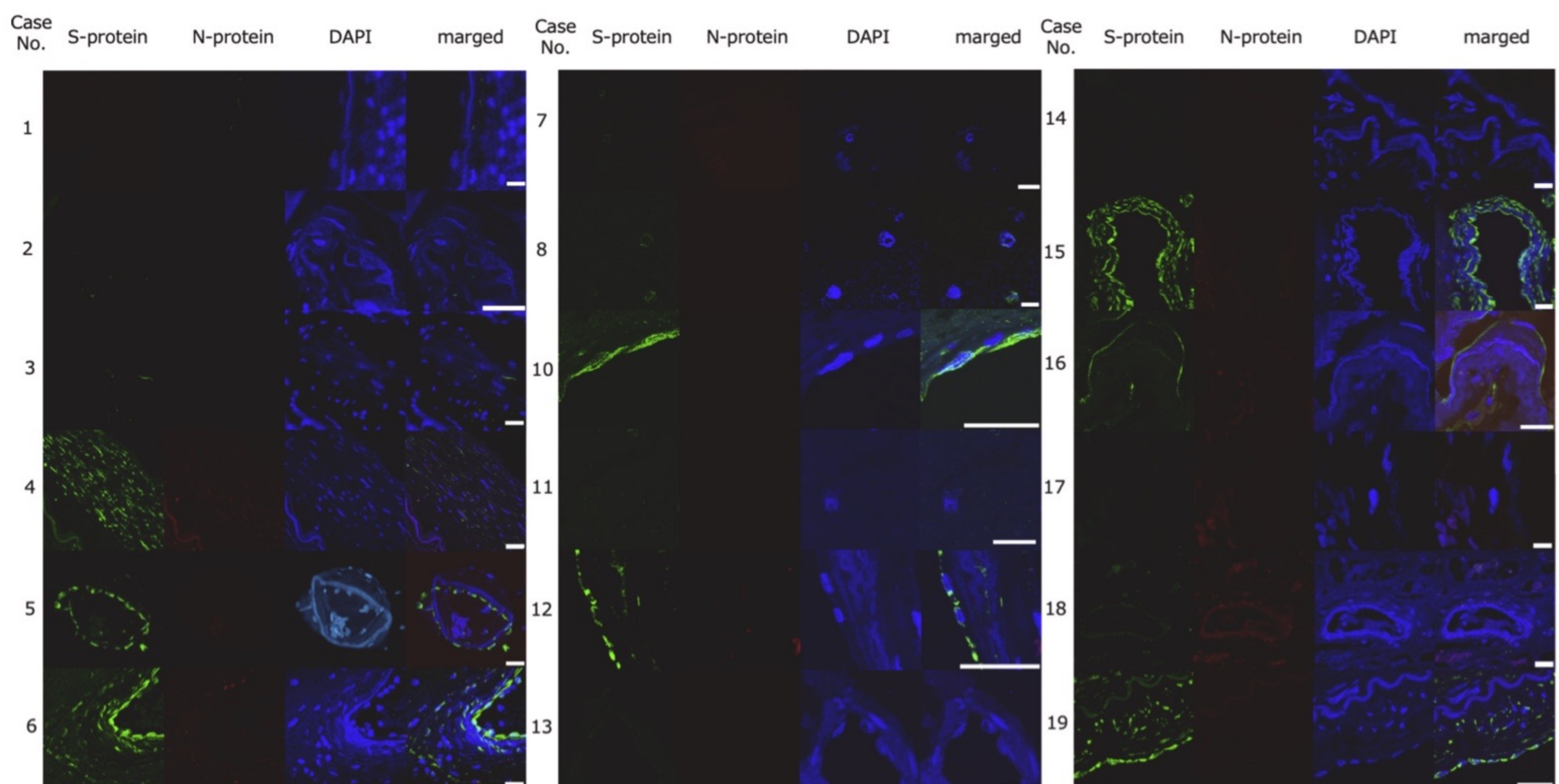


Fig. 2. Immunohistochemical staining of study cases. Cases 4, 5, 6, 10, 12, 15, 16, 18, and 19 showed positive staining for the SARS-CoV-2 spike protein. None of the cases showed positive staining for the nucleocapsid protein. The specimen of the case 9 is defective. Scale bar indicates 20 μm. S-protein; Spike protein, N-protein; Nucleocapsid protein, DAPI; 4',6-diamidino-2-phenylindole.

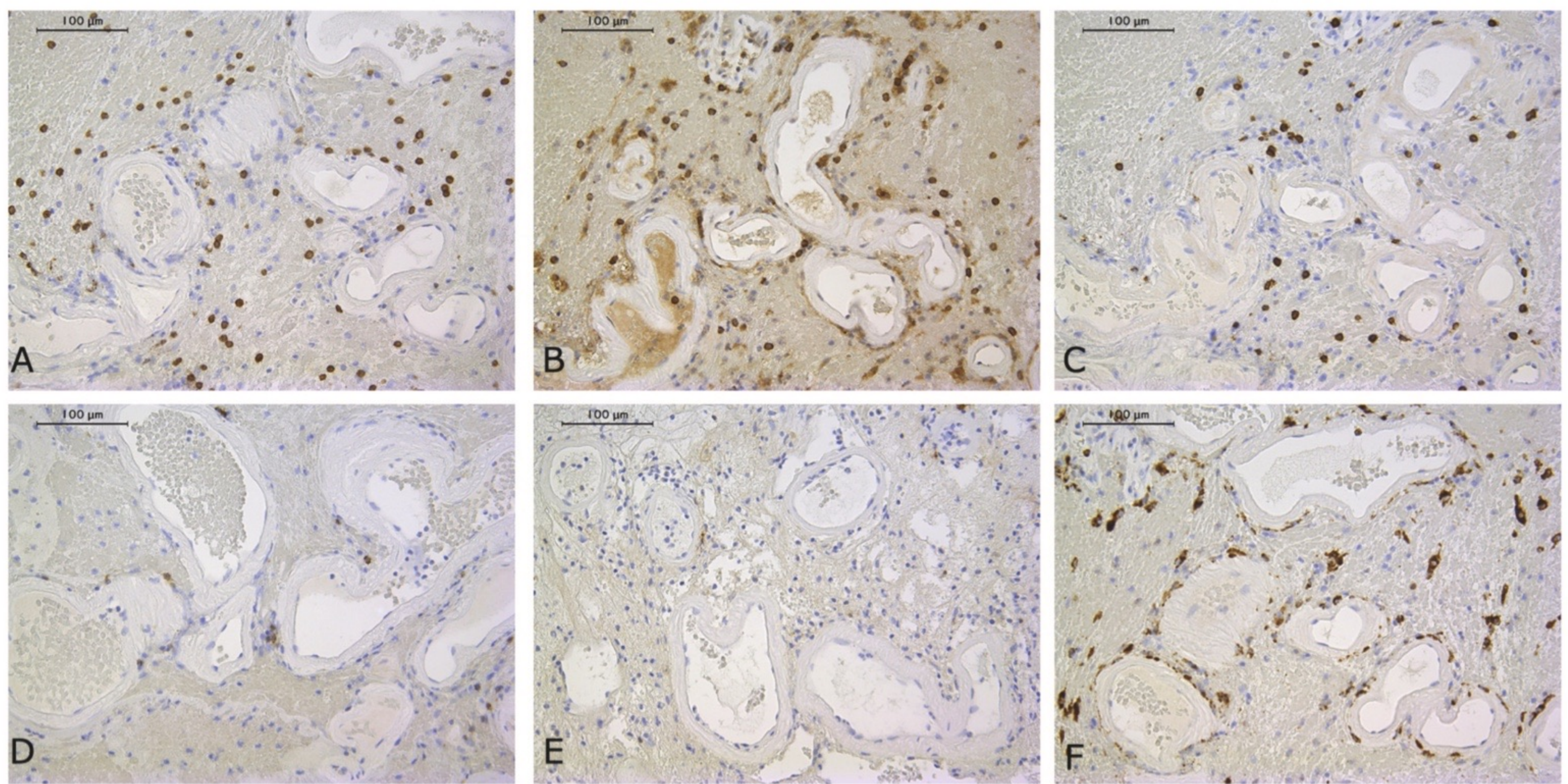


Fig. 3. Immunohistochemical staining of study case 16. An 88-year-old woman presented with subcortical hemorrhage, with history of seven vaccination and no history of COVID-19 infection. A: Immunohistochemical staining for CD3 demonstrated that CD3-positive cells infiltration. B: Immunohistochemical staining for CD4 demonstrated that CD4-positive cells are infiltration in the intima. C: Immunohistochemical staining for CD8 demonstrated that CD8-positive cells are infiltration in the adventitia. D: Immunohistochemical staining for CD20 demonstrated no obvious infiltration. E: Immunohistochemical staining for CD38 demonstrated no obvious infiltration. F: Immunohistochemical staining for CD68 demonstrated CD68-positive cells infiltration in the intima.

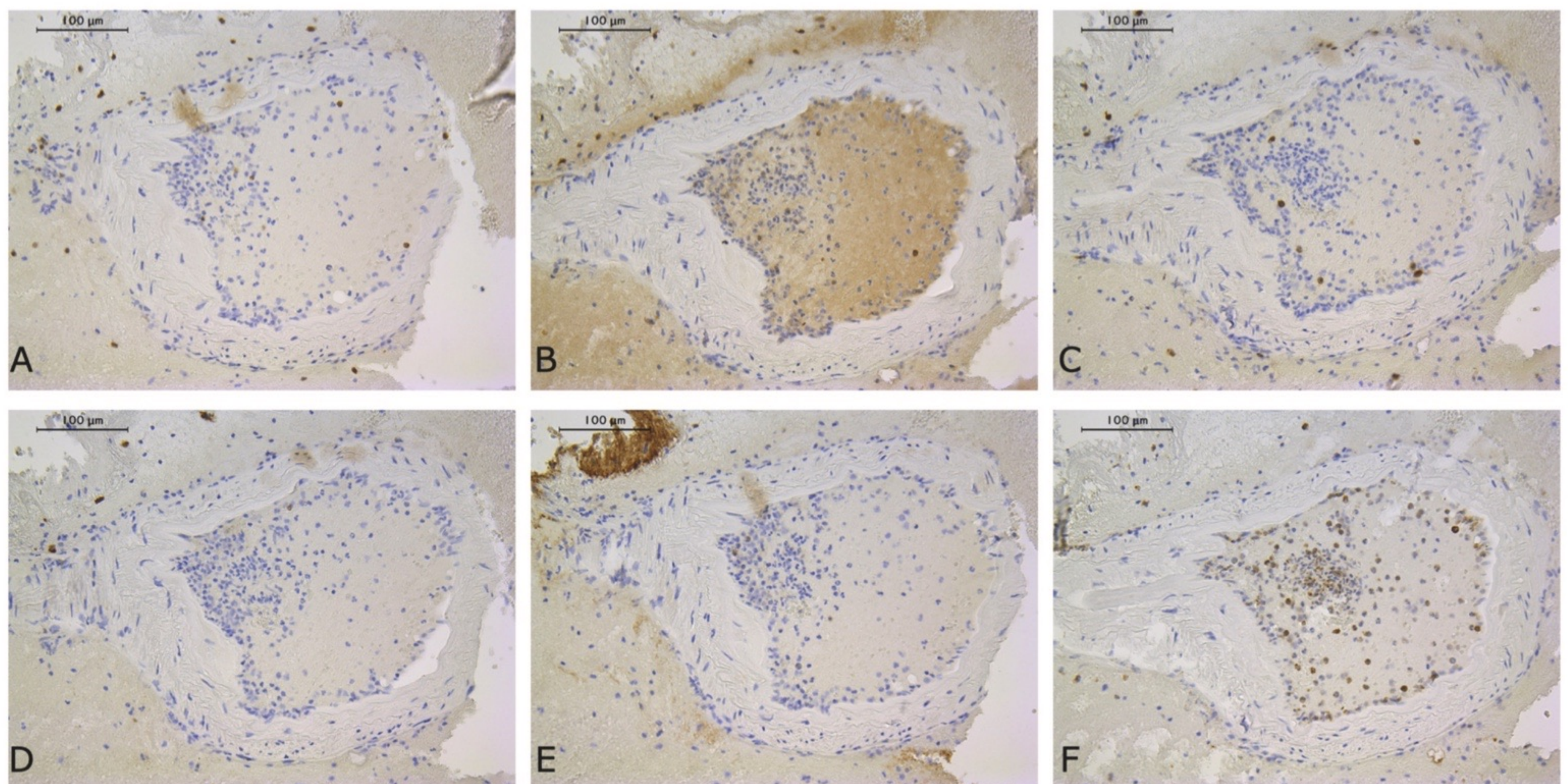


Fig. 4. Immunohistochemical staining of study case 2. A 75-year-old man presented with putaminal hemorrhage, with history of four vaccination and no history of COVID-19 infection. A: Immunohistochemical staining for CD3 demonstrated that no obvious CD3-positive cells infiltration. B: Immunohistochemical staining for CD4 demonstrated that no obvious CD4-positive cells infiltration. C: Immunohistochemical staining for CD8 demonstrated that no obvious CD8-positive cells infiltration. D: Immunohistochemical staining for CD20 demonstrated no obvious infiltration. E: Immunohistochemical staining for CD38 demonstrated no obvious infiltration. F: Immunohistochemical staining for CD68 demonstrated CD68-positive cells infiltration in the intima.

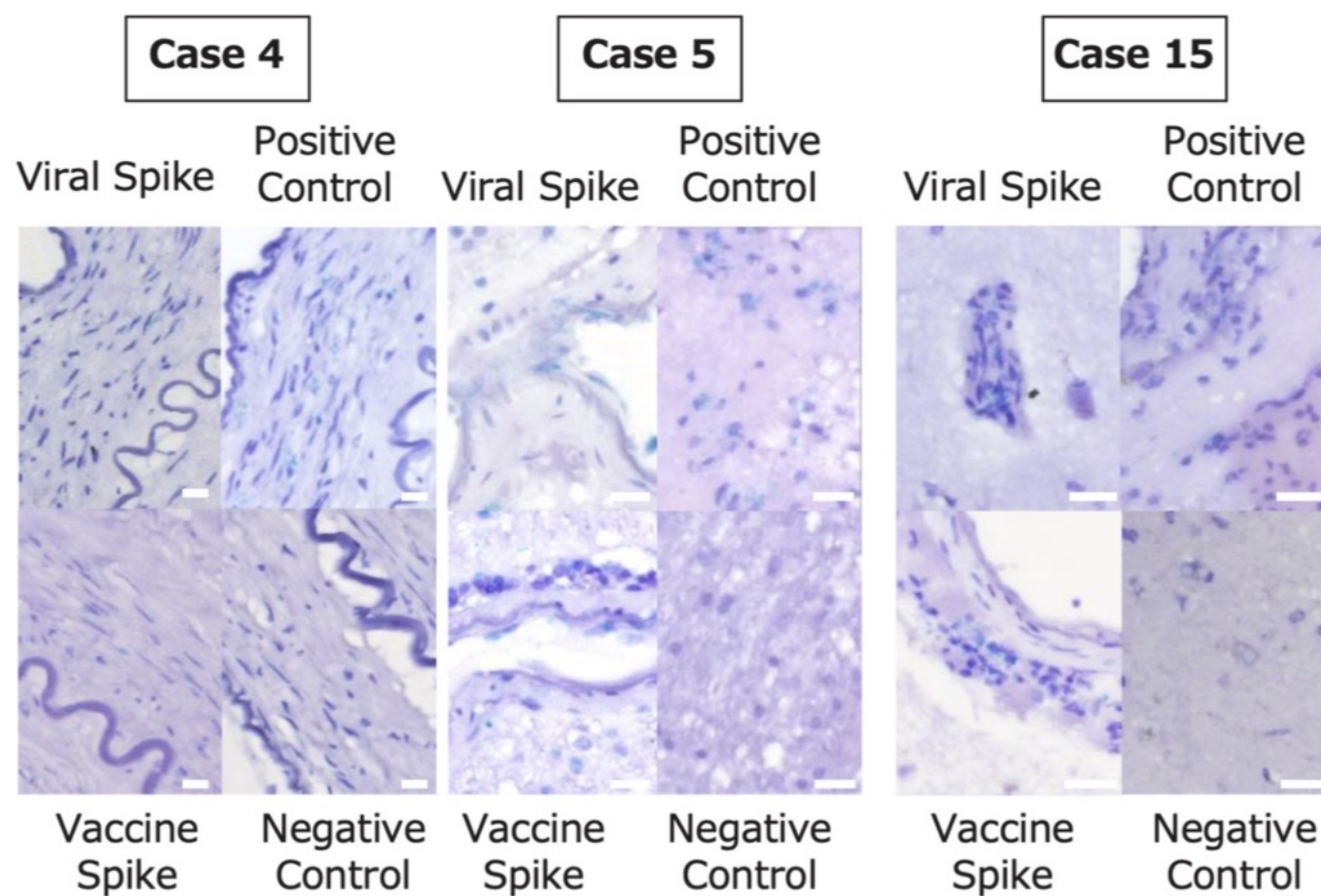


Fig. 5. Result of in situ hybridization of the case 4, 5 and 15. The specimens from cases 5 and 15 consist of brain tissue samples taken near the hematoma, while the specimen from case 4 is from the anterior cerebral artery, adjacent to the affected lesion, which was treated with trapping and excision of the aneurysm. Negative and positive controls were successfully validated for all cases. Furthermore, viral spike mRNA and vaccine-derived mRNA were detected as positive in all cases. A light blue luminescence indicates a positive result for mRNA specific to the probes. Scale bar indicates 20 μm . (For interpretation of the references to colour in this figure legend, the reader is referred to the web version of this article.)

hemorrhagic strokes [5,6]. The infection can induce a hypercoagulable state, disrupt endothelial function, and trigger an inflammatory response, collectively increasing stroke risk [6].

Although our study did not reveal infiltration of inflammatory cells suggesting active vasculitis in the intima, findings such as CD4-positive T-cell and CD68-positive cells infiltration into the intima, as well as CD8-positive cells infiltration into the adventitia, were observed. This may be because the specimen was taken from the surrounding brain tissues rather than the hemorrhagic point itself. Therefore, we hypothesize that expression of the spike protein drive T cell immunity, leading to the hemorrhagic stroke.

Recent studies have explored the biodistribution of SARS-CoV-2 mRNA vaccines in humans. Vaccine-associated mRNA has been detected in blood for at least 15 days post-vaccination [13], with some studies reporting its presence up to 28 days [14]. However, the biodistribution of SARS-CoV-2 mRNA vaccines in body tissues remains poorly understood. Lipid nanoparticles, which encapsulate the mRNA, may cross physiological barriers such as the blood–brain barrier, blood–placental barrier [15]. Additionally, recent research has examined the biodistribution and transferability of SARS-CoV-2 vaccines to human tissues. Concerns have been raised regarding potential autoimmune inflammatory reactions in terminally differentiated tissues like the heart and brain, triggered by in situ spike protein production [16,17]. Case reports have documented multifocal necrotizing encephalitis and myocarditis [16] as well as fatal multi-organ inflammation following SARS-CoV-2 vaccination [18]. These adverse effects were predominantly reported within a month after vaccination.

The present study revealed that lipid nanoparticle-modified mRNA vaccines could induce spike protein production in the vessel walls of the brain, persisting longer than previously anticipated. The actual behavior of mRNA vaccines within the human body may differ from what was previously believed. We suggest, based on the results of this study, that global replication studies should be conducted to verify the true safety profile of mRNA vaccines. These efforts are necessary to address potential concerns and ensure a comprehensive understanding of their long-term effects.

Recent research highlights significant sex differences in both acute

COVID-19 and post-acute sequelae of SARS-CoV-2 infection. During the acute phase, men tend to exhibit higher levels of innate immune cytokines and experience more severe symptoms, whereas women demonstrate stronger T cell activation [19]. In the long term, women are more likely to report persistent symptoms, such as dyspnea, fatigue, chest pain, and palpitations [20]. Studies have also shown that women are more likely to experience psychiatric or mood disorders, ear, nose, and throat issues, musculoskeletal problems, and neurological conditions as part of long COVID syndrome [21].

Although based on a small number of cases, the findings of the present study—particularly the significant sex-based differences in spike protein expression within the intima of cerebral arteries—may provide insights into the underlying mechanisms contributing to these observed disparities between sexes.

5. Limitation of the study

In our study, in situ hybridization detected both mRNA derived from the vaccine and mRNA from the SARS-CoV-2 virus. This suggests that the observed spike protein positive staining in patients with a history of SARS-CoV-2 vaccination, but no documented history of viral infection, cannot definitively be attributed to the vaccine alone. Notably, the nucleocapsid protein was consistently negative across cases, supporting the notion that our in situ hybridization method has high sensitivity and could detect trace amounts of mRNA, possibly reflecting unrecognized asymptomatic infections. These findings emphasize the need for caution in interpreting the presence of spike protein as exclusively vaccine-related.

Another limitation of this study is small sample size. It is necessary to expand the number of cases and clarify the true incidence and epidemiology. However, the fact that more than half of the cases in the present study express the spike protein in brain tissue is quite important. Based on these findings, global replication studies should be conducted to verify the true safety profile of mRNA vaccines.

6. Conclusions

Although the possibility of spike protein expression due to asymptomatic SARS-CoV-2 infection cannot be entirely excluded, this study demonstrated that mRNA vaccines for SARS-CoV-2 can result in prolonged spike protein expression within the intima of cerebral arteries, persisting for months after vaccination. This raises significant concerns regarding the biodistribution of lipid nanoparticle-encapsulated mRNA and the potential for long-term, yet rare, adverse events. Additionally, the notable presence of spike protein in vaccinated individuals and some inflammatory cell infiltration was observed in spike-positive vessels—particularly women—highlights potential sex-based differences in vaccine response. These results underscore the urgent global studies to replicate and expand upon these findings, ensuring a more comprehensive understanding of the long-term safety profile of mRNA vaccines.

Further research is also needed to differentiate between spike protein derived from vaccination and that resulting from undiagnosed asymptomatic SARS-CoV-2 infection. Improved detection methods and robust epidemiological studies could mitigate current limitations and better inform clinical and public health strategies. Ultimately, while mRNA vaccines remain a critical tool against COVID-19, ongoing evaluation of their long-term effects is essential for ensuring their safety and effectiveness.

Sources of Funding

This work was supported by Teishinkai Foundation.

CRedit authorship contribution statement

Nakao Ota: Writing – original draft, Resources, Project administration, Methodology, Investigation, Conceptualization. **Masahiko Itani:** Writing – review & editing, Validation, Investigation, Data curation. **Tomohiro Aoki:** Writing – review & editing, Validation, Methodology, Investigation, Data curation, Conceptualization. **Aki Sakurai:** Writing – review & editing, Supervision, Methodology. **Takashi Fujisawa:** Writing – review & editing, Resources, Data curation. **Yasuaki Okada:** Writing – review & editing, Resources, Data curation. **Kosumo Noda:** Writing – review & editing, Resources. **Yoshiki Arakawa:** Writing – review & editing, Supervision. **Sadahisa Tokuda:** Writing – review & editing, Funding acquisition. **Rokuya Tanikawa:** Writing – review & editing, Supervision, Conceptualization.

Declaration of competing interest

The authors declare that they have no known competing financial interests or personal relationships that could have appeared to influence the work reported in this paper.

Acknowledgements

We thank Shota Watanabe, Pharmacist at Sapporo Teishinkai Hospital, for being responsible for collecting the necessary data.

Appendix A. Supplementary data

Supplementary data to this article can be found online at <https://doi.org/10.1016/j.jocn.2025.111223>.

References

- [1] Baden LR, El Sahly HM, Essink B, Kotloff K, Frey S, Novak R, et al. Efficacy and Safety of the mRNA-1273 SARS-CoV-2 Vaccine. *N Engl J Med* 2021;384:403–16. <https://doi.org/10.1056/NEJMoa2035389>.
- [2] Polack FP, Thomas SJ, Kitchin N, Absalon J, Gurtman A, Lockhart S, et al. Safety and Efficacy of the BNT162b2 mRNA Covid-19 Vaccine. *N Engl J Med* 2020;383:2603–15. <https://doi.org/10.1056/NEJMoa2034577>.
- [3] Thomas SJ, Moreira Jr ED, Kitchin N, Absalon J, Gurtman A, Lockhart S, et al. Safety and Efficacy of the BNT162b2 mRNA Covid-19 Vaccine through 6 Months. *N Engl J Med* 2021;385:1761–73. <https://doi.org/10.1056/NEJMoa2110345>.
- [4] DeOre BJ, Tran KA, Andrews AM, Ramirez SH, Galie PA. SARS-CoV-2 Spike Protein Disrupts Blood-Brain Barrier Integrity via RhoA Activation. *J Neuroimmune Pharmacol* 2021;16:722–8. <https://doi.org/10.1007/s11481-021-10029-0>.
- [5] Divani AA, Andalib S, Di Napoli M, Lattanzi S, Hussain MS, Biller J, et al. Coronavirus Disease 2019 and Stroke: Clinical Manifestations and Pathophysiological Insights. *J Stroke Cerebrovasc Dis* 2020;29:104941. <https://doi.org/10.1016/j.jstrokecerebrovasdis.2020.104941>.
- [6] Qi X, Keith KA, Huang JH. COVID-19 and stroke: A review. *Brain Hemorrhages* 2021;2:76–83. <https://doi.org/10.1016/j.hest.2020.11.001>.
- [7] Wang Z, Yang Y, Liang X, Gao B, Liu M, Li W, et al. COVID-19 Associated Ischemic Stroke and Hemorrhagic Stroke: Incidence, Potential Pathological Mechanism, and Management. *Front Neurol* 2020;11:571996. <https://doi.org/10.3389/fneur.2020.571996>.
- [8] Markus HS, Brainin M. COVID-19 and stroke-A global World Stroke Organization perspective. *Int J Stroke* 2020;15:361–4. <https://doi.org/10.1177/1747493020923472>.
- [9] Ancau M, Liesche-Starnecker F, Niederschweiberer J, Krieg SM, Zimmer C, Lingg C, et al. Case Series: Acute Hemorrhagic Encephalomyelitis After SARS-CoV-2 Vaccination. *Front Neurol* 2021;12:820049. <https://doi.org/10.3389/fneur.2021.820049>.
- [10] Chui CSL, Fan M, Wan EYF, Leung MTY, Cheung E, Yan VKC, et al. Thromboembolic events and hemorrhagic stroke after mRNA (BNT162b2) and inactivated (CoronaVac) covid-19 vaccination: A self-controlled case series study. *EclinicalMedicine* 2022;50:101504. <https://doi.org/10.1016/j.eclinm.2022.101504>.
- [11] Sharifian-Dorche M, Bahmanyar M, Sharifian-Dorche A, Mohammadi P, Nomovi M, Mowla A. Vaccine-induced immune thrombotic thrombocytopenia and cerebral venous sinus thrombosis post COVID-19 vaccination; a systematic review. *J Neurol Sci* 2021;428:117607. <https://doi.org/10.1016/j.jns.2021.117607>.
- [12] Takeyama R, Fukuda K, Kouzaki Y, Koga T, Hayashi S, Ohtani H, et al. Intracerebral hemorrhage due to vasculitis following COVID-19 vaccination: a case report. *Acta Neurochir (Wien)* 2022;164:543–7. <https://doi.org/10.1007/s00701-021-05038-0>.
- [13] Fertig TE, Chitoui L, Marta DS, Ionescu VS, Cismasiu VB, Radu E, et al. Vaccine mRNA Can Be Detected in Blood at 15 Days Post-Vaccination. *Biomedicines* 2022; 10. <https://doi.org/10.3390/biomedicines10071538>.
- [14] Castruita JAS, Schneider UV, Mollerup S, Leineweber TD, Weis N, Bukh J, et al. SARS-CoV-2 spike mRNA vaccine sequences circulate in blood up to 28 days after COVID-19 vaccination. *APMIS* 2023;131:128–32. <https://doi.org/10.1111/apm.13294>.
- [15] Pateev I, Seregina K, Ivanov R, Reshetnikov V. Biodistribution of RNA Vaccines and of Their Products: Evidence from Human and Animal Studies. *Biomedicines* 2023; 12. <https://doi.org/10.3390/biomedicines12010059>.
- [16] Morz M. A Case Report: Multifocal Necrotizing Encephalitis and Myocarditis after BNT162b2 mRNA Vaccination against COVID-19. *Vaccines (Basel)* 2022;10. <https://doi.org/10.3390/vaccines10101651>.
- [17] Polykretis P, Donzelli A, Lindsay JC, Wiseman D, Kyriakopoulos AM, Morz M, et al. Autoimmune inflammatory reactions triggered by the COVID-19 genetic vaccines in terminally differentiated tissues. *Autoimmunity* 2023;56:2259123. <https://doi.org/10.1080/08916934.2023.2259123>.
- [18] Nushida H, Ito A, Kurata H, Umemoto H, Tokunaga I, Iseki H, et al. A case of fatal multi-organ inflammation following COVID-19 vaccination. *Leg Med (Tokyo)* 2023; 63:102244. <https://doi.org/10.1016/j.legalmed.2023.102244>.
- [19] Takahashi T, Ellingson MK, Wong P, Israelow B, Lucas C, Klein J, et al. Sex differences in immune responses that underlie COVID-19 disease outcomes. *Nature* 2020;588:315–20. <https://doi.org/10.1038/s41586-020-2700-3>.
- [20] Pela G, Goldoni M, Solinas E, Cavalli C, Tagliaferri S, Ranzieri S, et al. Sex-Related Differences in Long-COVID-19 Syndrome. *J Womens Health (Larchmt)* 2022;31: 620–30. <https://doi.org/10.1089/jwh.2021.0411>.
- [21] Sylvester SV, Rusu R, Chan B, Bellows M, O'Keefe C, Nicholson S. Sex differences in sequelae from COVID-19 infection and in long COVID syndrome: a review. *Curr Med Res Opin* 2022;38:1391–9. <https://doi.org/10.1080/03007995.2022.2081454>.